



**PATIENT**

Romeo Zybala

**SPECIES**

Feline

**BREED**

DSH

**SEX**

Male Neutered

**AGE**

8 years

**WEIGHT**

12.38lbs

**PRESENTING CLINICAL SIGNS**

History: Romeo is referred to evaluate a heart murmur. Euthyroid. He has a good appetite and is active and playful. CV/RESP: NSR, grade II/VI murmur noted best on sternum, PSS, lung fields clear, compressible thorax. BP: 160-170mmHg.

**ECHOCARDIOGRAM FINDINGS**

2D, m-mode, color flow and Doppler imaging is available.

**Left ventricle:** The LV diameter is normal with adequate myocardial function. The LV wall dimensions are normal. There is mild fibrosis of the endocardium. The endocardium appears mildly remodeled. The papillary muscles appear hyperechoic and normal in dimension.

**Left atrium:** The left atrium is normal. No obvious smoke or thrombi seen.

**Mitral valve:** The mitral valve is normal in structure and mobility. No obvious systolic anterior motion is seen. No MR.

**Aortic valve/aorta:** The aortic valve is normal in morphology and mobility. Normal aortic outflow velocity; laminar flow. No aortic insufficiency.

**Right ventricle:** Normal right ventricular diameter and morphology indicating no overt evidence of pulmonary arterial hypertension.

**Right atrium:** The right atrium is normal in dimension.

**Tricuspid valve:** The tricuspid valve appears normal with trace tricuspid regurgitation.

**Pulmonic valve/pulmonary artery:** The pulmonic valve is normal in morphology and mobility. No pulmonic insufficiency. Normal RVOT velocity; laminar flow.

**Pericardium/other:** No pericardial or pleural effusion noted. No obvious cardiac masses.

**Heart rhythm:** ECG reveals a sinus rhythm with an average HR of 170bpm.

**INTERPRETED BY**

Maggie Machen  
Lamy, DVM  
DACVIM (Cardiology)

**2-Dimensional Measurements**

Ao diam (cm)	1.2
LA diam (cm)	1.2
LA:Ao (Swe)	1.0
IVS thickness (cm)	0.52
LVID diastole (cm)	1.4
PW thickness (cm)	0.54
LVID systole (cm)	0.7
FS (%)	50

**Doppler Measurements**

PV Vmax (m/s)	0.5
AoV Vmax (m/s)	0.86
MR Vmax (m/s)	NA
TR Vmax (m/s)	NA
TR PG (mmHg)	NA

**IMAGING**

**PERFORMED BY**

Pamela Harrigan,  
RDCS

**INTERPRETATION OF THE FINDINGS**

Overtly normal cardiac structure and function are identified. Mild remodeling fibrosis of the left ventricular wall is noted, which is likely a normal age-related variant. No significant valve leaks are noted, and flow through the great vessels is normal in velocity. No definitive cause is identified for the murmur in this study, making it likely physiologic in origin (i.e., secondary to tachycardia, volume changes, etc.).

**HOSPITAL NAME**

Mass Veterinary Services

**REFERRING VET**

Dr. Masloski

Prognosis is open.

**RECOMMENDATIONS**

- Given these findings, no medications are indicated.
- No cardiac contraindication for general anesthesia. Should fluid or steroid therapy be indicated in the future, any cat should be monitored for intolerance (changes in RR/RE).
- Monitor at home for signs of cardiac compromise, including respiratory changes and/or signs of a blood clot event (paralysis, neurologic changes).

**INVOICE**

22330

**DATE**

12/7/21



**PATIENT**

Romeo Zybala

**PLAN**

- Recommend recheck echocardiogram in 1 year to assess for any progressive issues or development of disease the pre-existing murmur may mask.

**SPECIES**

Feline

**BREED**

DSH

**SEX**

Male Neutered

**AGE**

8 years

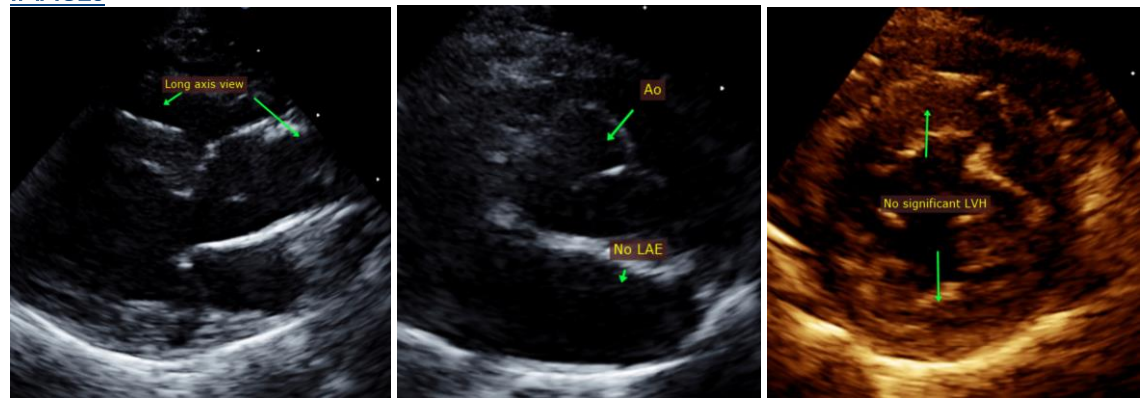
**WEIGHT**

12.38lbs

**INTERPRETED BY**

Maggie Machen  
Lamy, DVM  
DACVIM (Cardiology)

**IMAGES**



The information and recommendations provided are based on the images presented by the referring veterinarian. No evaluation can be communicated regarding pathology that was not visible in the image/video clips provided.

Thank you for this referral. This report was generated using transcription software, and minor dictation errors may be present. If the clinical or image interpretation does not parallel your findings or if I can be of any further assistance, please contact me.

**Maggie Machen Lamy, DVM**  
**Diplomate of the American College of Veterinary Internal Medicine (Cardiology)**  
info@sonopath.com

Echocardiogram performed by: Pamela Harrigan, RDCS  
Pet Animal Ultrasound Service (4paus.com)

**IMAGING PERFORMED BY**

Pamela Harrigan,  
RDCS

**HOSPITAL NAME**

Mass Veterinary  
Services

**REFERRING VET**

Dr. Masloski

**INVOICE**

22330

**DATE**

12/7/21